

A Case of Presumptive Marshall Bundle Conduction Between the Left Atrium and Left Superior Pulmonary Vein During Box Isolation

Kenji Hashimoto¹, Michihiro Kobayashi², Takumi Kakegawa², Kota Suzuki², Tomochika Negishi², Ippei Tsuzuki¹, Yuta Seki¹, Susumu Ibe¹, Terumasa Yamashita¹, Hiroshi Miyama¹, Taishi Fujisawa¹, Yoshinori Katsumata¹, Takehiro Kimura¹, Seiji Takatsuki^{1*}

¹Department of Cardiology, Keio University School of Medicine, 35 Shinanomachi, Shinjuku-ku, Tokyo 160-8582, Japan.

²Office of Medical Engineer, Keio University School of Medicine, 35 Shinanomachi, Shinjuku-ku, Tokyo 160-8582, Japan.

*Corresponding author: Seiji Takatsuki, seiji.takatsuki@gmail.com

Copyright: © 2022 Author(s). This is an open-access article distributed under the terms of the Creative Commons Attribution License (CC BY 4.0), permitting distribution and reproduction in any medium, provided the original work is cited.

Abstract

A 65-year-old man with symptomatic persistent atrial fibrillation was referred for initial radiofrequency catheter ablation. He underwent box isolation to simultaneously isolate all four pulmonary veins (PVs) and the posterior wall of the left atrium (LA). During the box isolation with a double lasso catheter positioned in both the left superior and right superior PVs, the atrial fibrillation terminated spontaneously. After the box lesion set was created, conduction was still observed between the LA and PVs. After an additional radiofrequency energy delivery to the bottom line of the box lesion, the activation sequence of the PVs became uniform during sinus rhythm and pacing from the coronary sinus (CS), indicating that only one more conduction pathway was present. The 3-dimensional map revealed that the earliest activation site within the box lesion was located in the anterior aspect of the left superior PV during pacing from the CS, whereas that of the LA during pacing from the superior right PV within the box was on the posterolateral LA wall below the left inferior PV. When a 2 Fr electrode catheter was inserted into the vein of Marshall (VOM) and paced within the BOX, VOM potentials preceded CS potentials. When the left superior PV anterior wall, the earliest site of excitation within the box, was energized, simultaneous posterior pulmonary vein wall isolation was completed. We experienced a case in which Marshall bundle conduction between the left atrium and the pulmonary vein was assumed.

Keywords

Atrial fibrillation
Catheter ablation
Marshall bundle

1. Introduction

Pulmonary vein isolation is a well-established ablation technique for atrial fibrillation, and the efficacy

of single-ring box isolation, which simultaneously isolates bilateral pulmonary veins and the left atrial posterior wall, has been reported for persistent atrial

fibrillation^[1,2]. Although recent advances in equipment have greatly improved the durability of pulmonary vein isolation, pulmonary vein re-conduction is still a frequent cause of AF recurrence after ablation, and reliable pulmonary vein and box isolation is very important^[3].

However, pulmonary vein isolation is sometimes difficult, and epicardial conduction is known to be one of the causes^[4]. In the present study, we attempted box isolation and applied full circumferential energization, but box isolation was not completed and mapping of bidirectional conduction was performed to identify the entrances and exits, and we report a case in which conduction via the Marshall bundle was assumed.

2. Case Example

A 65-year-old male had a chief complaint of shortness of breath with a history of hypertension. He had no family history reported and a medical history of 60 mg edoxaban, 2.5 mg bisoprolol, 20 mg azilsartan, and 5 mg amlodipine.

The patient was first diagnosed with atrial fibrillation at a medical check-up three months ago. The patient was admitted to the hospital for atrial fibrillation ablation for rhythm control due to persistent atrial fibrillation with shortness of breath. On admission, height 163.0 cm, weight 61.3 kg, blood pressure 144/89 mmHg, heart rate 67 bpm, heart sounds S1 → S2 → S3 (-) S4 (-), irregular, no heart murmur, clear respiratory sounds, no leg edema. His chest radiograph showed a cardiothoracic ratio of 48.9% with no pulmonary congestion and pleural effusion. The 12-lead ECG on admission indicated he has atrial fibrillation, a heart rate of 94 bpm, and an incomplete right bundle branch block. The 24-hour Holter ECG also indicated he has atrial fibrillation, a total heart rate of 155,540 beats, ventricular extrasystoles of 1108 beats, no pauses longer than 2 seconds, and tachycardia (≥ 100 bpm) 289 times. His transthoracic echocardiogram showed a left ventricular ejection fraction (mSimpson method) of 63.2%, left ventricular diastolic/end-systolic diameter of 43/29 mm, ventricular septal/posterior wall thickness

of 11/10 mm, aortic diameter of 36 mm, left atrial diameter of 37 mm, and mild mitral regurgitation.

The patient was in atrial fibrillation at the start of the ablation, and ablation was performed under deep sedation using the 3D mapping system CARTO (Biosense Webster). 2 ring-shaped multi-electrode mapping catheters and 1 ablation catheter were inserted into the left atrium after the atrial septal puncture. The patient was energized point by point in the following order: anterior right pulmonary vein, bottom line, anterior left pulmonary vein, and roof line. During energization of the anterior left pulmonary vein, atrial fibrillation was converted to atrial tachycardia and the tachycardia stopped (**Figure 1**). Mapping under the pace in the box along the energized line revealed an early potential in the bottom line just above the esophagus, so additional energization was performed. The order of excitation was altered. The order of excitation in the pulmonary vein was the same during sinus rhythm and coronary sinus pace, suggesting a single residual conduction (**Figure 2**). The time from the distal coronary sinus electrode to the earliest left pulmonary vein during sinus rhythm and coronary sinus pace was almost identical at 115 ms and 120 ms, respectively. Mapping outside the box during pacing from the right pulmonary vein, which is within the box, showed the earliest excitation site (exit) in the posterior wall of the left atrium below the left inferior pulmonary vein (**Figure 3**). Mapping above the entrance, closer to the entrance, revealed a slower excitation, as the anatomical location of the entrance and exit approximated the general running of the VOM and ligament of Marshall (LOM), suggesting that the Marshall bundle is the most likely route to the epicardial side. The anatomical position of the VOM and the LOM was similar to that of the common VOM and the LOM, so we suspected intra- and extra-cardiac conduction through the epicardial side via the Marshall bundle (**Figure 4**). A 2 Fr electrode catheter was inserted into the VOM from within the catheter; the VOM was so narrow that only the distal three poles

of the 2 Fr electrode catheter were inserted into the VOM. Under the pace of the left superior pulmonary vein, conduction was observed in the order of the pulmonary vein, VOM, and central coronary sinus, and it was assumed that conduction inside and outside the box was via the Marshall bundle (Figure 5). To avoid energization in the pulmonary vein, the anterior carina of the left pulmonary vein, where the Marshall bundle is assumed to run, was anatomically energized, but it was ineffective. The anterior carina of the left

superior pulmonary vein, which was the earliest site of excitation in the box under coronary sinus pacing outside the BOX, was energized, conduction inside and outside the box disappeared, and box isolation was completed (Figure 6). The patient was found to have conduction to the left superior pulmonary vein but not outside the box from the anterior carina (Figure 7). The patient has remained medication-free for one year postoperatively without recurrence of atrial fibrillation or tachycardia.

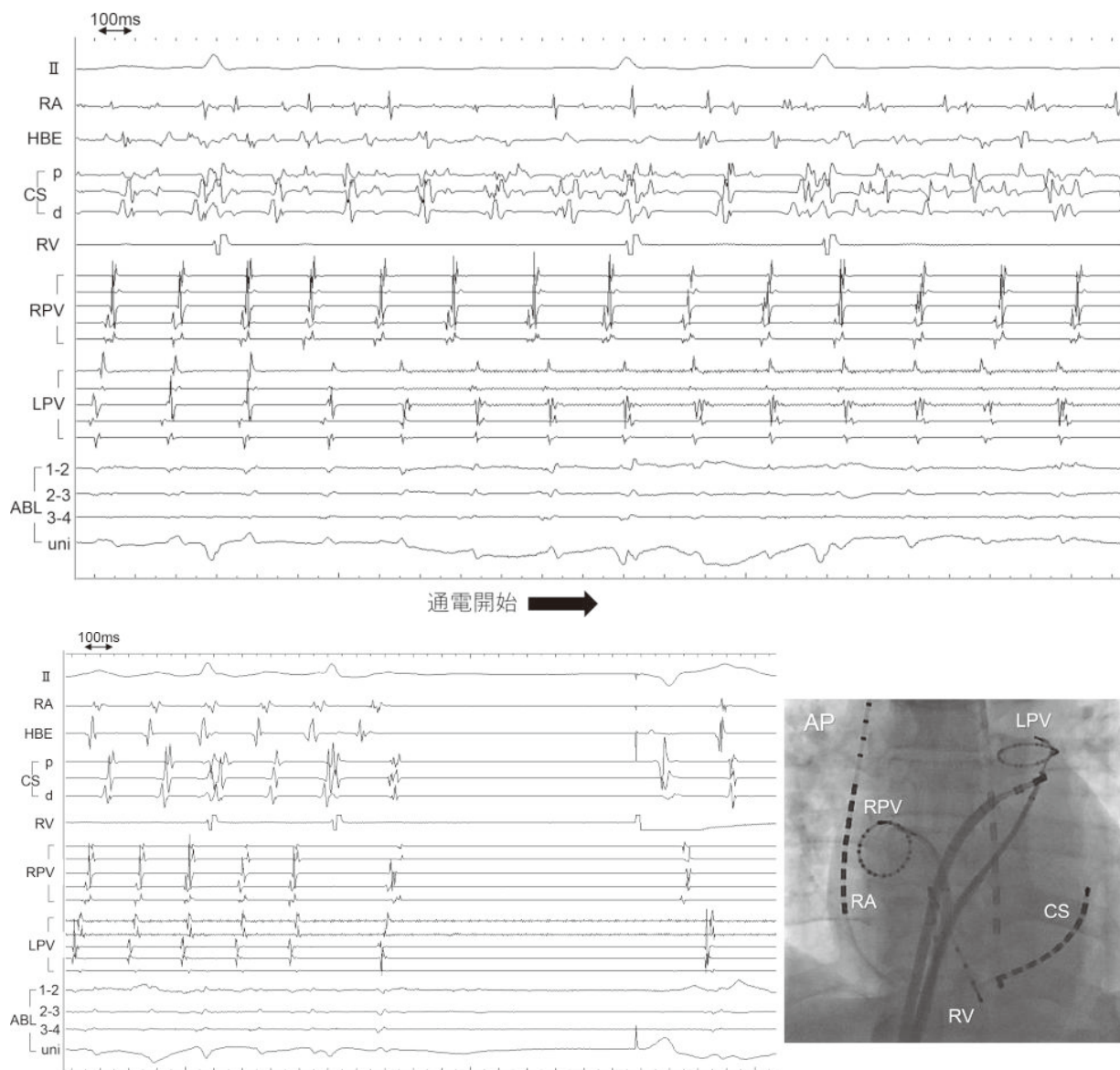


Figure 1. Findings during cessation of atrial fibrillation. Top: intracardiac ECG at the start of energization; bottom left: intracardiac ECG at the end of tachycardia; bottom right: fluoroscopic image (frontal view). Atrial fibrillation stopped during the energization of the anterior left pulmonary vein. ABL: ablation catheter; CS: coronary sinus; d: distal part; HBE: His bundle electrogram; LPV: left pulmonary vein; p: proximal part; RA: right atrium; RPV: right pulmonary vein; RV: right ventricle; uni: unipolar potential.

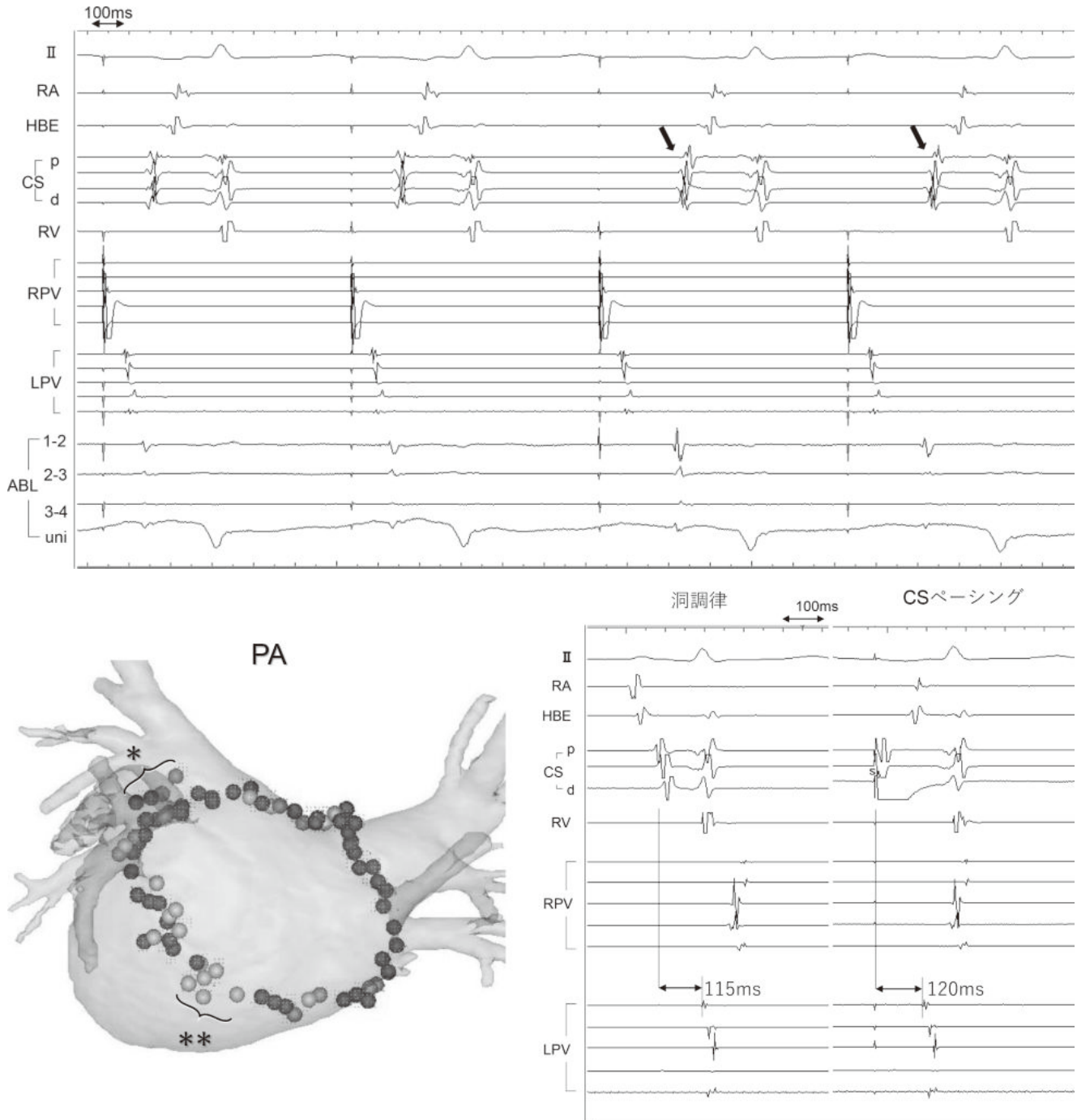


Figure 2. Energization points on the 3D map and intracardiac ECG findings. Top: After the box area was energized circumferentially, additional energization to the bottom line during the pace of the pulmonary vein changed the order of excitation in the coronary sinus. Bottom left: Energisation points. Points illustrate all energization points required to complete box isolation. * indicates the energization point in the left superior pulmonary vein that was finally energized to the site of electrical coupling with the Marshall bundle. ** indicates the energization point at which the oesophageal temperature rose above 38°C. Lower right: intracardiac ECG during sinus rhythm and coronary sinus pacing. The order of excitation of the multi-electrode catheters placed in the right and left pulmonary veins was identical. Therefore, intra- and extra-box conduction was considered to be at one remaining site. The time from the distal coronary sinus electrode to the earliest left pulmonary vein during sinus rhythm and coronary sinus pace was 115 ms and 120 ms, respectively. Abbreviations are listed in **Figure 1** legend.

Figure 3. Bidirectional 3D activation map findings after box line creation. Top left: the earliest excitation site to the box was identified by creating an activation map within the box under the coronary sinus (outside the box) pacing. The earliest excitation site was found in the upper left pulmonary vein. Top right: the earliest excitation site from the box was identified by creating an activation map outside the box under the pacing of the pulmonary vein (within the box). The earliest excitation site was found in the posterior wall of the left atrium below the left inferior pulmonary vein. Left and right inferior: entrance and exit were anatomically distant from each other, with a distance of 44.9 mm.

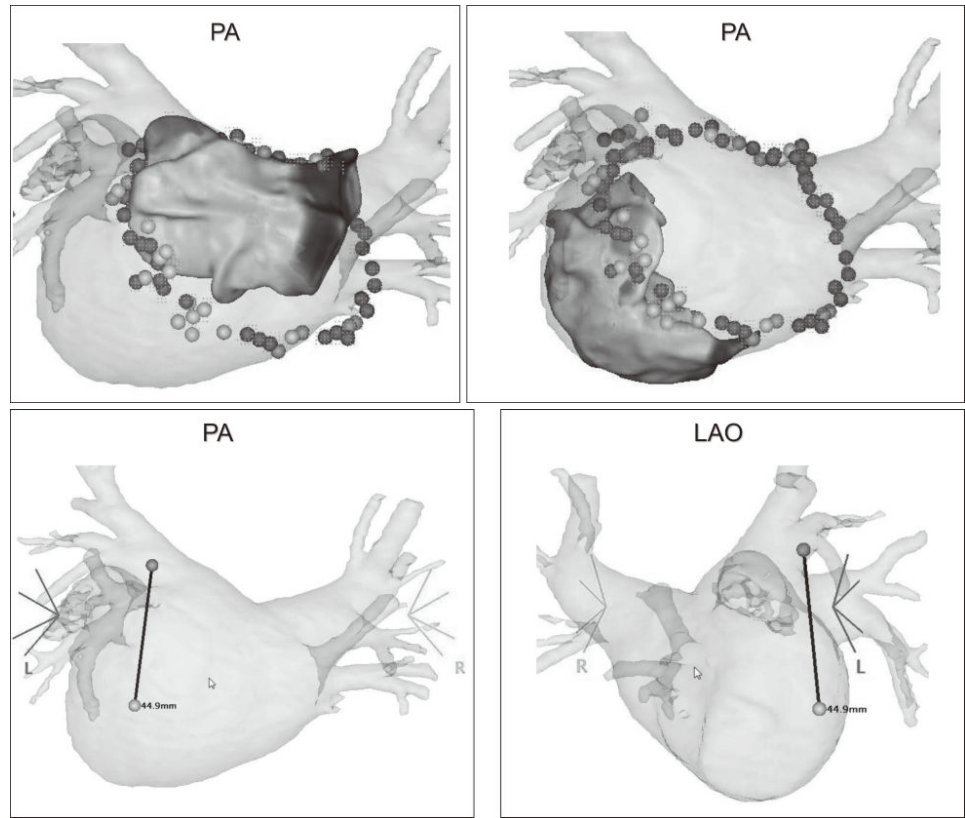


Figure 4. Marshall venography findings (right anterior oblique position). The 6 Fr Multi-purpose catheter was used to select and contrast the VOM in the coronary sinus. A narrow VOM was depicted.

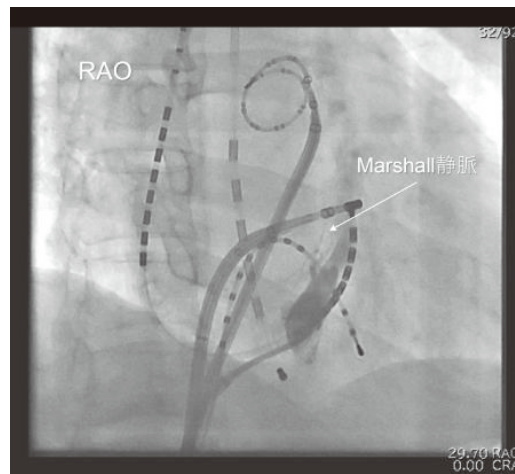
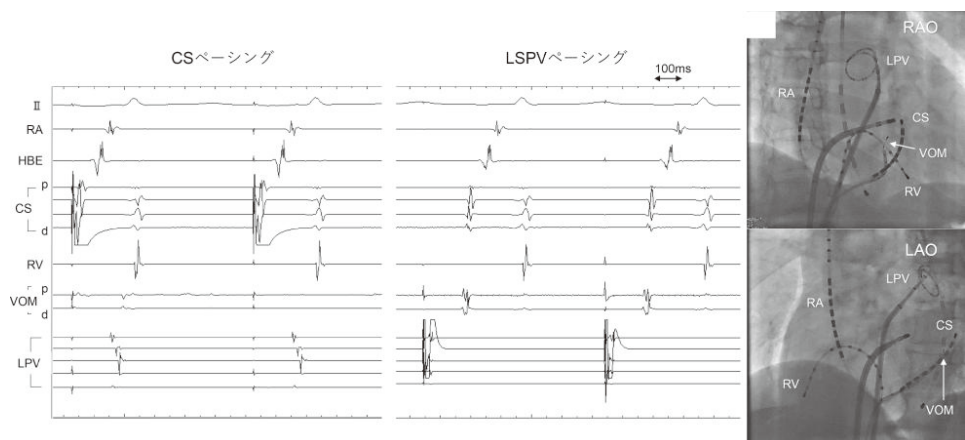


Figure 5. Intracardiac ECG findings after electrode catheter insertion in the VOM. Left: intracardiac ECG of coronary sinus pacing; middle: intracardiac ECG of pulmonary vein pacing; right: fluoroscopic image of catheter placement. VOM: vein of Marshall; Abbreviations are listed in **Figure 1** legend.



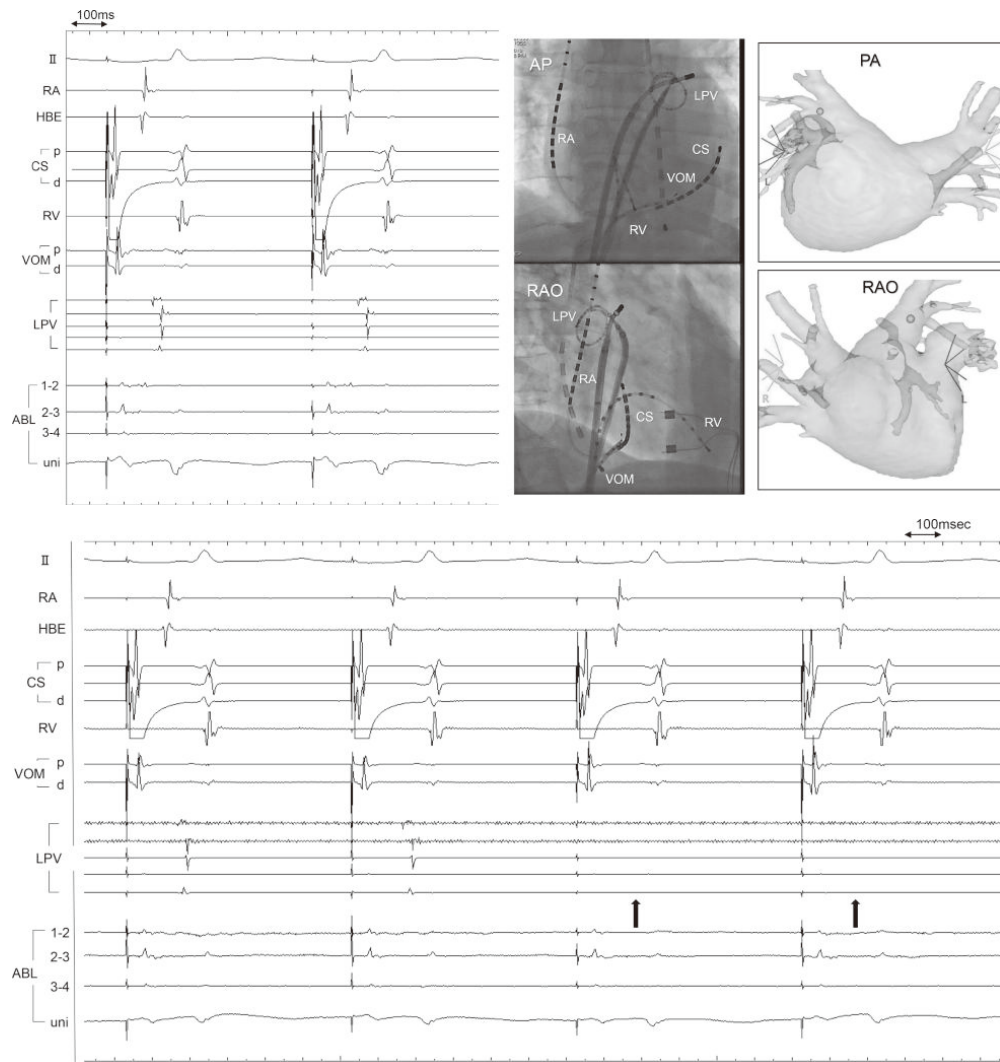


Figure 6. Findings during successful energization. Top left: potentials at the site of successful ablation; top middle: fluoroscopic image; top right: 3D map; bottom: anterior left superior pulmonary vein energized, which was the earliest excited site in the BOX under coronary sinus pacing, completing box isolation. Abbreviations are listed in **Figure 1** and **5** legends.

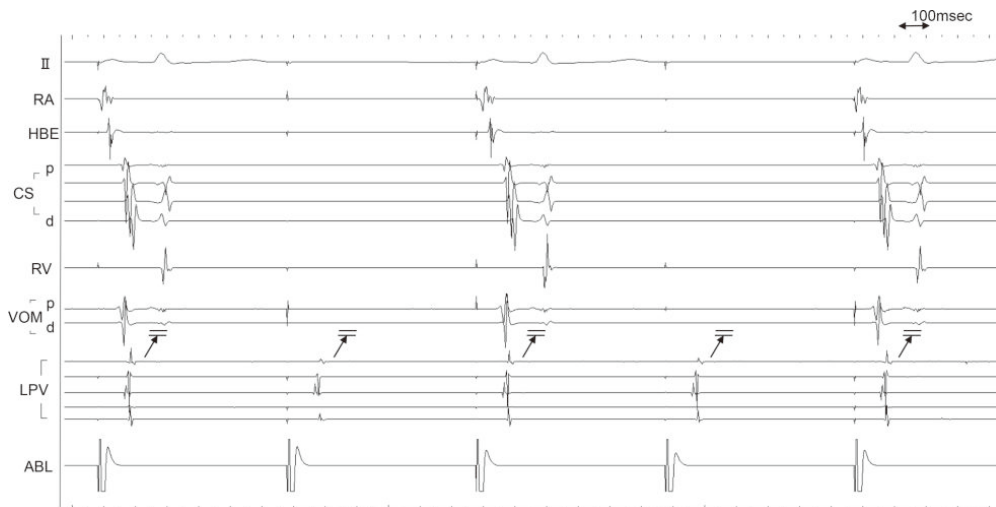


Figure 7. Intracardiac ECG findings after completion of box isolation. The findings were that the intra-box pace captured the left superior pulmonary vein, but the excitement did not propagate outside the box. Abbreviations are listed in **Figure 1** and **5** legends.

3. Consideration

In this case, when single-ring box isolation was performed for persistent atrial fibrillation, the presence of epicardial conduction via the Marshall bundle was assumed: the VOM and LOM, which is the remnant tissue of the regressed left common main vein and runs on the epicardial side, has been shown to have electrical connections with the surrounding endocardial myocardium, including the coronary sinus muscle bundle, left atrial myocardium and left pulmonary vein muscle bundle^[5]. Han *et al.* found a single electrical connection between the Marshall bundle and the endocardial side in 17% of cases, but multiple connections in the rest^[6]. Chee *et al.* mapped the electrical entrances and exits of the left pulmonary vein in patients in whom left pulmonary vein isolation had not been completed after full circumferential energization, and identified those in which the entrances were in the anterior carina of the left pulmonary vein and the exits were in the left posterior wall. The effect of Marshall bundle conduction on pulmonary vein isolation was investigated. Conduction through the Marshall bundle was observed in 8.4% of cases after circumferential radiofrequency energization for isolation of the left pulmonary vein, and 98% of cases were successfully isolated by energizing the anterior carina of the left pulmonary vein additionally^[7]. However, in their study, no electrode catheter was inserted into the VOM, and it was not proven to be complete via the VOM.

In this case of symptomatic persistent atrial fibrillation, radiofrequency energization was performed to isolate the box, and a 3D activation map was created to identify the entrances and exits under pace from inside and outside the box once single residual conduction was identified. Mapping from the exit upwards in the box to approach the entrance during a certain pulmonary vein pace showed a slowing of conduction in the opposite direction when approaching the entrance. The conduction was slowed when approaching the direction of the entrances. In addition, when there is conduction between the left atrium

and the pulmonary vein anterior to the left superior pulmonary vein during the pace in the box, conduction to the right atrium is faster due to the proximity of the exit from the box and the Bachman bundle, but in this case, conduction to the coronary sinus, near the His bundle and the higher right atrium was in that order, and conduction to the higher right atrium was relatively slow. The fact that conduction to the higher right atrium was relatively slower than that to the anterolateral left pulmonary vein suggested that there was no conduction to the anterolateral left pulmonary vein and that the exit from the box was down the left inferior pulmonary vein. In addition, the anatomical location of the entrances and exits was similar to that of the VOM and the LOM, suggesting conduction in and out of the box via the Marshall bundle. The conduction time from the distal electrode of the coronary sinus to the earliest left pulmonary vein was almost the same during sinus rhythm and coronary sinus pace in the lower diagram in **Figure 2**, which also suggested that the excitation to the left pulmonary vein was via the coronary sinus and Marshall bundle during sinus rhythm. In this case, angiography of the coronary sinus was performed and the VOM branching from the coronary sinus was observed, so a 2 Fr electrode catheter was inserted and the potential was observed. The results suggest that the excitation propagated through the pulmonary vein, the VOM, and the central coronary sinus in that order. The anterior carina of the left pulmonary vein, where the Marshall bundle generally runs and is considered to be a successful energization site in most cases, was first energized anatomically, but this was ineffective^[7]. The 2 Fr electrode catheter placed in the VOM was retracted compared to when it was inserted, and only the distal 2 poles were inserted into the VOM. Although it may not be accurate to determine the order of excitation from the 2 poles alone, the order of excitation under the CS pace of the 2 Fr electrode catheter after successful BOX isolation was distal to proximal and did not change before or after isolation. This finding led us to infer that intra- and extra-box

conduction before isolation was conducted from the endocardial to epicardial side further distal to the distal end of the catheter placed in the VOM and from epicardial to endocardial side in the left superior pulmonary vein. The limitation is that this finding could not be observed directly in this case because the VOM was narrow and the 2 Fr electrode catheter could not go deep enough, and the entire left atrium was not mapped on the activation map. However, by observing in detail the proximal potential of the VOM and the endocardial activation around the entrances and exits, we were able to interpret the conduction by the Marshall bundle as described above. In this case, the box isolation was assumed to have been successful because the connection between the Marshall bundle and the pulmonary vein could be disrupted, although there may still be multiple epicardial and endocardial connections due to the Marshall bundle.

Although ethanol injection into the VOM was not performed in this case, there is a high probability that chemical ablation with ethanol injection would have completed box isolation and may have been more collateral to the conduction of the Marshall bundle. However, as there were no intraoperative findings in

the present case to suggest that the Marshall bundle was pro-arrhythmic, the endpoint of the case was the completion of box isolation by energizing the connection with the pulmonary vein, which was assumed to be the distal end of the Marshall bundle.

In this case, activation mapping was performed in both directions in a patient with residual intra- and extra-ventricular conduction, and it was suspected that the epicardial and endocardial connections were interrupted and that by disrupting the conduction assumed to be mediated by the Marshall bundle, the intra- and extra-ventricular conduction could be disrupted. The case was considered to be a case of intra- and extra-box conduction disruption by disrupting conduction through the Marshall bundle.

4. Conclusion

We report a case in which BOX isolation was completed by energizing the anterior left superior pulmonary vein (LSPV), as conduction between the left atrium and left superior pulmonary vein was assumed via the epicardial conduction by the Marshall bundle when BOX isolation was performed.

Disclosure statement

The authors declare no conflict of interest.

Acknowledgments

We thank Mr. John Martin for his guidance and encouragement in English language writing.

References

- [1] Bai R, Di Biase L, Mohanty P, et al, 2016, Proven Isolation of the Pulmonary Vein Antrum With or Without Left Atrial Posterior Wall Isolation in Patients With Persistent Atrial Fibrillation. *Heart Rhythm*, 13(1): 132–140. <https://doi.org/10.1016/j.hrthm.2015.08.019>.
- [2] Morillo CA, Verma A, Connolly SJ, et al, 2014, Radiofrequency Ablation vs Antiarrhythmic Drugs as First-Line

- Treatment of Paroxysmal Atrial Fibrillation (RAAFT-2): a Randomized Trial. *JAMA*, 311(7): 692–700. <https://doi.org/10.1001/jama.2014.467>.
- [3] Rajappan K, Kistler PM, Earley MJ, et al, 2008, Acute and Chronic Pulmonary Vein Reconnection After Atrial Fibrillation Ablation: a Prospective Characterization of Anatomical Sites. *Pacing Clin Electrophysiol*, 31(12): 1598–1605. <https://doi.org/10.1111/j.1540-8159.2008.01232.x>.
- [4] Barrio-Lopez MT, Sanchez-Quintana D, Garcia-Martinez J, et al, 2020, Epicardial Connections Involving Pulmonary Veins: the Prevalence, Predictors, and Implications for Ablation Outcome. *Circ Arrhythm Electrophysiol*, 13(1): e007544. <https://doi.org/10.1161/CIRCEP.119.007544>.
- [5] Makino M, Inoue S, Matsuyama TA, et al, 2006, Diverse Myocardial Extension and Autonomic Innervation on Ligament of Marshall in Humans. *J Cardiovasc Electrophysiol*, 17(6): 594–599. <https://doi.org/10.1111/j.1540-8167.2006.00375.x>.
- [6] Han S, Joung B, Scanavacca M, et al, 2010, Electrophysiological Characteristics of the Marshall Bundle in Humans. *Heart Rhythm*, 7(6): 786–793. <https://doi.org/10.1016/j.hrthm.2010.02.028>.
- [7] Chee J, Kalogeropoulos AP, Almasry I, et al, 2021, Identification and Endocardial Ablation of the Ligament of Marshall for Pulmonary Vein Isolation. *JACC Clin Electrophysiol*, 7(3): 283–291. <https://doi.org/10.1016/j.jacep.2020.08.027>.

Art & Technology Publishing remains neutral with regard to jurisdictional claims in published maps and institutional affiliations.